

RETROSPECTIVE STUDY OF ULTRASONOGRAPHIC FEATURES OF MACROCALCIFICATION IN THYROID NODULE AT TERTIARY CARE CENTER

Dr. Mahipal Singh^{1*}, Dr. Devendra K Verma², Dr. Anil Jangid³

1. Assistant Professor, 2. Assistant Professor, 3. Senior Resident, Department of Radiology, JNU Institute for Medical Sciences and Research Centre, Jaipur

*Corresponding author – **Dr. Mahipal Singh**

Email id – drmahipalsinghchoudhary@gmail.com

Received: 20/02/2020

Revised:02/03/2020

Accepted: 06/03/2020

ABSTRACT

Background: Thyroid lesions vary from non-neoplastic to neoplastic, the most common thyroid lesion is multinodular goiter which is followed by thyroid tumors. Most of the thyroid tumors are benign and the malignant thyroid lesions are accounting only for 1.5% of all cancers. **Material & Methods:** The present cross-sectional, retrospective study was conducted at department of radiology of our tertiary care hospital. The study duration was of one year from January 2018 to December 2019. Clearance from Institutional Ethics Committee was taken before start of study. **Results:** Most common presentation was swelling in front on neck however 3 patients presented with lymphadenopathy at level 2 and 3. In the present study, on USG evaluation most common finding was multinodular goiter among 13 patients which was followed by colloid nodule among 12 patients. Solitary thyroid nodule was found among 10 patients which was followed by malignancy among 5 patients. In the present study, on USG evaluation the size of the nodule found to be ranges from 1.2x1.2 to 7x7 cm. **Conclusion:** We found that nodules with macrocalcification also had chances of microcalcification which could be a reason that nodules associated with macrocalcification have positive rates for malignancy.

Keywords: Thyroid nodule, Ultrasonography, Multinodular goiter.

INTRODUCTION

Thyroid gland is a butterfly shaped endocrine gland which is situated anatomically in the anterior aspect of root of the neck and comprises of two bulky lateral lobes which are connected by a thin isthmus (1). Thyroid gland secretes several hormones such as triiodothyronine (T3), thyroxine (T4) and calcitonin. The prevalence and magnitude of all the thyroid disorders are associated and dependent on numerous risk factors and confounding factors (2). The thyroid hormones control the metabolism of macromolecules, oxygen consumption and the basal metabolic rate (BMR) of body cells and are essential for normal growth and maturation of the body as well as they are essential for proper development of the peripheral and central nervous system (3).

Pathologic evaluations of lesions of the thyroid gland are of research importance because they directly affect the functioning of other organs of body and along with that histopathological result forms the basis of highly effective medical and surgical treatment (4). The range of thyroid lesions are varied from congenital lesions to hyperplastic or metabolic goiter and inflammatory to neoplastic thyroid lesions. It is now well documented that thyroid gland lesions and disorders are the second most common endocrine disorders reported from India as well as all around the globe (5).

Thyroid lesions vary from non-neoplastic to neoplastic, the most common thyroid lesion is multinodular goiter which is followed by thyroid

tumors (6). Most of the thyroid tumors are benign and the malignant thyroid lesions are accounting only for 1.5% of all cancers. However, among the endocrine malignancies thyroid cancers represents approximately 92% of all endocrine cancers. Among the thyroid malignancies, the most common is papillary carcinoma which is followed by follicular carcinoma, medullary carcinoma, anaplastic carcinoma and lymphoma, while metastasis are reported rarely (7). Hence, as the incidence of thyroid carcinomas are increasing nowadays, so the present study was conducted to estimate the burden of diseases and to determine the histopathological pattern of thyroid lesions in thyroidectomy specimens.

Hence, present study was conducted to assess the ultrasonographic features of neck for thyroid gland at tertiary care centre.

MATERIALS & METHODS

The present cross-sectional, retrospective study was conducted at department of radiology of our tertiary care hospital. The study duration was of one year from January 2018 to December 2019. A sample size of 40 was calculated at 90% confidence interval at 5% acceptable margin of error by epi info software version 7.2. Clearance from Institutional Ethics Committee was taken before start of study. Clinical examination history, ultrasound findings and detailed history of routine blood investigations were recorded from hospital records after institutional permission.

Ultrasound evaluation of all patients with patient in supine with neck in extension was done using ultrasound machines superficial probe with 5.5 - 12.5 MHz transducer. Nodule size, volume, location, echogenicity (isoechoic, hyperechoic or hypoechoic), texture (solid, cystic or mixed), presence and type of calcification (microcalcification, peripheral macrocalcification or parenchymal macrocalcification), presence of hypoechoic halo and vascularization pattern were recorded for all the patients. Calcifications which are measured less than 2 mm were labeled as microcalcification and calcifications of more than 2 mm in diameter (with an acoustic shadow) were labeled as macrocalcification. Ultrasonographic findings were correlated with FNAC findings.

Data were entered in the MS office 2010 spread sheet and Epi Info v7. Data analysis was carried out using SPSS v22. Qualitative data was expressed as percentage (%) and Pearson's chi square test was

used to find out statistical differences between the study groups and sensitivity, specificity, positive predictive value and negative predictive value were calculated. If the expected cell count was < 5 in more than 20% of the cells then Fisher's exact test was used. All tests were done at alpha (level significance) of 5%; means a significant association present if p value was less than 0.05.

RESULTS

In the present study a total of 40 study participants were enrolled. Out of them 70% patients were female and 30% patients were male and the female to male sex ratio was 2.3: 1. Age of study participants was ranged from 18- 68 years of age with the mean age of 43±7.4 years. Most common presentation was swelling in front on neck however 3 patients presented with lymphadenopathy at level 2 and 3. In the present study, on USG evaluation most common finding was multinodular goiter among 13 patients which was followed by colloid nodule among 13 patients. Solitary thyroid nodule was found among 10 patients which was followed by malignancy among 5 patients. In the present study, on USG evaluation the size of the nodule found to be ranges from 1.2x1.2 to 7x7 cm. (Table 1)

Table1: Distribution of patients according to incidence of different sonographic findings.

Calcification	Total no	MNG	STN	Colloid nodule	Malignant
Macro-calcification	25	10	5	9	1
Micro-calcification	7	0	1	3	3
Micro+macro	8	3	4	0	1
Total	40	13	10	12	5

Fig 1: Coarse calcification finding on USG in thyroid nodule.

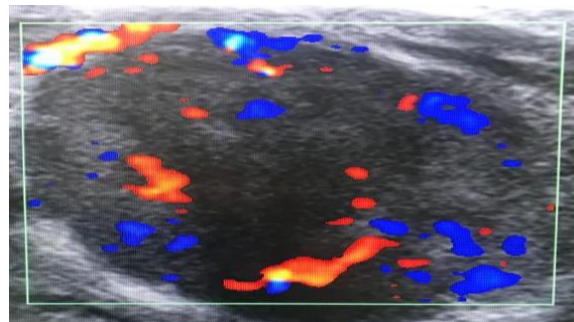
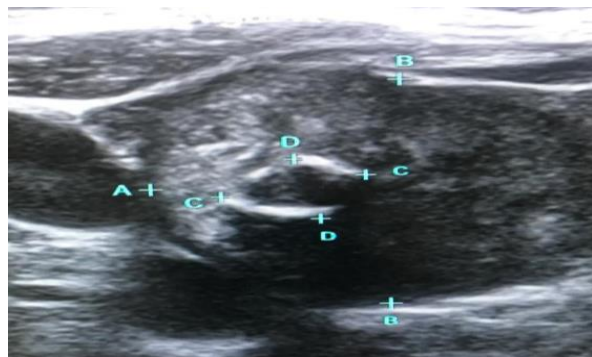


Fig 2: Histopathological papillary carcinoma finding on USG in thyroid nodule.



The other main finding on USG evaluation was calcification. Out of the total 27 patients had macrocalcifications, 6 patients had microcalcifications and 7 patients had both micro as well as macrocalcifications. On further evaluation we found that out of those 27 patients with macrocalcification, 11 were benign, 6 were solitary nodules, 9 were colloid nodule and 1 were malignant on USG. Out of those 6 patients with microcalcification, 2 had solitary nodule, 2 had colloid nodule and 2 had malignancy. Out of those 7 patients with micro as well macrocalcification were diagnosed as multinodular goiter in 3 patients, solitary nodule in 3 patients and malignant in 1 cases. In the present study on USG evaluation increased vascularity was found in 13 patients. Out of these 13 patients only 4 patients were malignant on USG. Out of these 13 patients, 4 had multinodular goiter, 3 had solitary thyroid nodule and 2 had colloid nodule.

DISCUSSION

According to world health organization, 7% of the global population is reported to have clinically apparent goiter. Majority of these goiter patients are living in developing countries where the etiopathogenesis is iodine deficiency (8). Non neoplastic thyroid enlargement reported in the form of multinodular goiter and solitary or diffuse goiter. Thyroid disorders are generally more prevalent among females. Benign cancers of thyroid gland are more prevalent than neoplastic lesions of thyroid gland and the ratio was reported to be as high as 10:1 (9). In the present study a total of 40 study participants were enrolled. Out of them 70% patients were female and 30% patients were male and the female to male sex ratio was 2.3: 1. Age of study participants was ranged from 18- 68 years of age with the mean age of 43 ± 7.4 years. Most common presentation was swelling in front on neck however

3 patients presented with lymphadenopathy at level 2 and 3.

In the present study, on USG evaluation most common finding was multinodular goiter among 13 patients which was followed by colloid nodule among 13 patients. Solitary thyroid nodule was found among 10 patients which was followed by malignancy among 5 patients. In the present study, on USG evaluation the size of the nodule found to be ranges from 1.2x1.2 to 7x7 cm. Similar results were found in a study conducted by Kiran Rao et al among patients who were presented with thyroid nodule and reported similar results to the present study (10). Similar results were found in a study conducted by Bomeli SR et al among patients who were presented with thyroid nodule and reported similar results to the present study (11).

In the present study out of the total, 27 patients had macrocalcifications, 6 patients had microcalcifications and 7 patients had both micro as well as macrocalcifications. On further evaluation we found that out of those 27 patients with macrocalcification, 11 were benign, 6 were solitary nodules, 9 were colloid nodule and 1 were malignant on USG. Out of those 6 patients with microcalcification, 2 had solitary nodule, 2 had colloid nodule and 2 had malignancy. Out of those 7 patients with micro as well macrocalcification were diagnosed as multinodular goiter in 3 patients, solitary nodule in 3 patients and malignant in 1 cases. In the present study on USG evaluation increased vascularity was found in 13 patients. Out of these 13 patients only 4 patients were malignant on USG. Out of these 13 patients, 4 had multinodular goiter, 3 had solitary thyroid nodule and 2 had colloid nodule. Similar results were found in a study conducted by Naina V et al among patients who were presented with thyroid nodule and reported similar results to the present study (12).

CONCLUSION

We concluded from the present study that macrocalcification is solely not a good indicator for malignancy. We found that nodules with macrocalcification also had chances of microcalcification which could be a reason that nodules associated with macrocalcification have positive rates for malignancy. The results of present study cannot be generalize on general population because of small sample size. Further elaborative studies needed to explore the topic.

REFERENCES

1. Segni M. Disorders of the Thyroid Gland in Infancy, Childhood and Adolescence [Internet]. Endotext. MDText.com, Inc.; 2000. Available from: <http://www.ncbi.nlm.nih.gov/pubmed/25905261>
2. Garg M, Mahalle N, Hari Kumar KVS. Laboratory evaluation of thyroid function: Dilemmas and pitfalls. *Med J Dr DY Patil Univ* [Internet]. 2016;9(4):430. Available from: <http://www.mjdrdypu.org/text.asp?2016/9/4/430/186054>
3. Hoang J. Thyroid nodules and evaluation of thyroid cancer risk. *Australas J Ultrasound Med* [Internet]. 2010;13(4):33. Available from: <https://www.ncbi.nlm.nih.gov/pmc/articles/PMC5024877/>
4. Nussey S, Whitehead S. The thyroid gland. 2001; Available from: <https://www.ncbi.nlm.nih.gov/books/NBK28/>
5. Zamora EA, Cassaro S. Thyroid Nodule [Internet]. StatPearls. StatPearls Publishing; 2018. Available from: <http://www.ncbi.nlm.nih.gov/pubmed/30571043>
6. Holzheimer RG. Benign nodular thyroid disease. 2001; Available from: <https://www.ncbi.nlm.nih.gov/books/NBK6893/>
7. Nachiappan AC, Metwalli ZA, Hailey BS, Patel RA, Ostrowski ML, Wynne DM. The Thyroid: Review of Imaging Features and Biopsy Techniques with Radiologic-Pathologic Correlation. *RadioGraphics* [Internet]. 2014 Mar 1;34(2):276–93. Available from: <http://pubs.rsna.org/doi/10.1148/rg.342135067>
8. Medeiros-Neto G. Multinodular Goiter [Internet]. Endotext. MDText.com, Inc.; 2000. Available from: <http://www.ncbi.nlm.nih.gov/pubmed/25905424>
9. Khattak RM, Ittermann T, Nauck M, Below H, Völzke H. Monitoring the prevalence of thyroid disorders in the adult population of Northeast Germany. *Popul Health Metr* [Internet]. 2016 Dec 8;14(1):39. Available from: <http://www.ncbi.nlm.nih.gov/pubmed/27833458>
10. Rao K, Goyal VP. Comparative Study of FNAC and Excisional Biopsy in Thyroid Swelling. *Indian J Otolaryngol Head Neck Surg*. 2010 Oct;62(4):415–6.
11. Bomeli SR, LeBeau SO, Ferris RL. Evaluation of a thyroid nodule [Internet]. Vol. 43, *Otolaryngologic Clinics of North America*. 2010. p. 229–38. Available from: <http://www.ncbi.nlm.nih.gov/pubmed/20510711>
12. Verma N, Mohindroo S, Azad R, Mohindroo NK. Macrocalcification in thyroid nodule. *Int J Res Med Sci*. 2017;5(7):2960.

How to cite this article: Singh M., Verma D.K., Jangid A., Retrospective study of ultrasonographic features of macrocalcification in thyroid nodule at tertiary care center. *Int.J.Med.Sci.Educ* 2020;7(2):17-20