

A STUDY CORRELATING THE CLINICAL PICTURE OF INFECTIVE ENDOCARDITIS WITH ECHOCARDIOGRAPHIC FINDINGS ESTABLISHING RELATIONSHIP WITH AGE

Dr. Mridul Bhushan^{1*}, Dr.Prem Singh².

1- Associate professor, Government Medical College Kannauj, 2, Associate Professor and Head, Department of Medicine, Ganesh Shankar Vidyarthi Memorial Medical College and Hospital ,Kanpur.

***Email id of corresponding author- drmridul80@gmail.com**

Received: 25/02/2017

Revised: 02/07/2017

Accepted: 23/07/2017

ABSTRACT

Background: Infective endocarditis (IE) is the infection of a native or prosthetic heart valve, the endocardial surface of heart, or an indwelling cardiac device. Highly destructive staphylococci have now overtaken oral streptococci as the most common cause. The present study was conducted with the objective of establishing the relationship between the symptoms of diseases with the severity (echocardiographic findings), and establish the most common age group and the most common organism, causing severe disease (severe valvular infection) and associated complications. **Methods:** After taking clearance from the ethics committee of the institute, the patients coming to the department of cardiology, Government Medical College, Kannauj with suspected IE were thoroughly investigated after their consent. 2D echocardiography was done in all the subjects to confirm the diagnosis and the severity of valvular lesion. Several other investigations were done. **Results:** Majority of the patients in our study were found to be in the age group of 11 to 20 years. Fever was the most common symptom in all patients. Pallor and cardiac murmurs were the most common signs. Staph. aureus was the etiological agent in majority of the patients. The echocardiographic findings significantly correlated with the clinical picture and complications. Complications included severe anaemia, heart and renal failure and stroke. Staph organism was the most common etiological agent involved in our study. **Conclusion:** If the Echocardiography shows the involvement of cardiac valves, the clinical picture is usually severe. The change in pattern of the disease and the correlation of the clinical picture with the echocardiographic findings has been demonstrated without a doubt in our study.

KEY WORDS: Infective endocarditis, 2D Echocardiography, Staph aureus, valvular lesions.

INTRODUCTION

Infective endocarditis (IE) is the infection of a native or prosthetic heart valve, the endocardial surface of heart, or an indwelling cardiac device. Earlier, IE was caused mainly by microorganisms originating in the oral cavity (oral streptococci). The situation has dramatically changed in the last several years (1). With the exception of intravenous drug users and those with congenital heart disease, patients typically

are elderly. The focus of infection is frequently on prosthetic material within the heart: for example, cardiac devices (pacemakers, implantable cardioverter defibrillators and cardiac resynchronisation therapy) or prosthetic heart valves. Also, the bacteria underlying IE have changed: highly destructive staphylococci have now overtaken oral streptococci as the most common cause (2, 3)

Acute IE, caused typically by staphylococcus aureus, presents with marked toxicity, valvular destruction and metastatic infection. Subacute infective endocarditis, usually caused by viridians streptococci, enterococci etc presents with moderate toxicity and rarely causes metastatic infection (4). Echocardiography has significantly improved the ability to confirm or reject the diagnosis of infective endocarditis (5).

Since the pattern and epidemiology of IE has changed so much in the last century, it becomes essential to correlate the risk factors and the clinical presentation of the disease with the extent of valvular destruction and metastatic infection. Also, the severity of the disease, both in terms of symptoms and echocardiographic findings, can be studied with respect to the age of the patient and the causative organism.

The present study was conducted with the objective of establishing the relationship between the symptoms of diseases with the severity (echocardiographic findings), and establish the most common age group and the most common organism, causing severe disease (severe valvular infection) and associated complications.

MATERIALS AND METHODS

The present study was conducted in the department of cardiology, Government Medical College, Kannouj After taking clearance from the ethics committee of the institute, the patients coming to the department of cardiology with suspected IE were thoroughly investigated after their consent. A performa was prepared and complete history and clinical examination was done accordingly. Routine examinations like complete haemogram, urine analysis, Chest X Ray and ECG were done. Blood cultures were done. Dukes criteria was used for diagnosis (6). 2D echocardiography was done in all the

subjects to confirm the diagnosis and the severity of valvular lesion. Further investigations were done to confirm any complications.

The data was collected and statistical analysis was done.

RESULTS

Out of all the patients that attended the cardiac OPD, 52 patients were suspected of having IE and were included in the study. Out of them, 30 were males and 22 were females. The age distribution of the subjects is shown in Table No. 1. Majority of the patients in our study were found to be in the age group of 11 to 20 years.

TABLE NO. 1: INCIDENCE OF IE ACROSS DIFFERENT AGE GROUPS

AGE	No. of patients
<10 years	0
11-20 years	21
21-30 years	13
31-40 years	5
41-50 years	8
51-60 years	2
>60 years	3
Total	52

The symptoms of the patients are shown in Figure No. 1 and the signs are shown in Figure No. 2. Fever was most commonly shown across all the patients. Cardiac murmurs were shown by all of the patients. Pallor, oligouria and clubbing were also fairly common.

Figure 1: Symptoms of IE

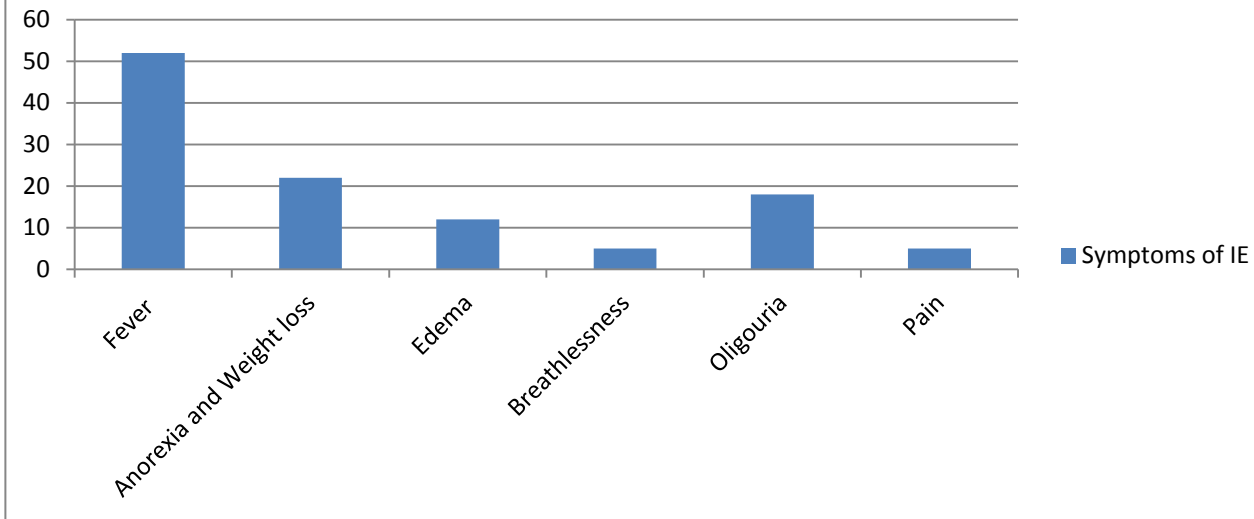
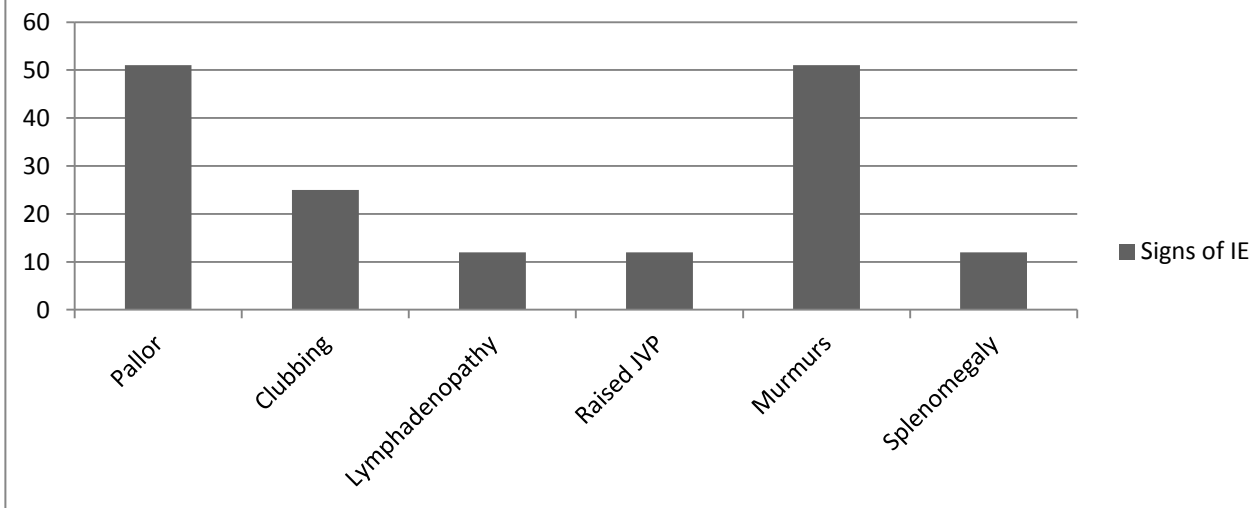


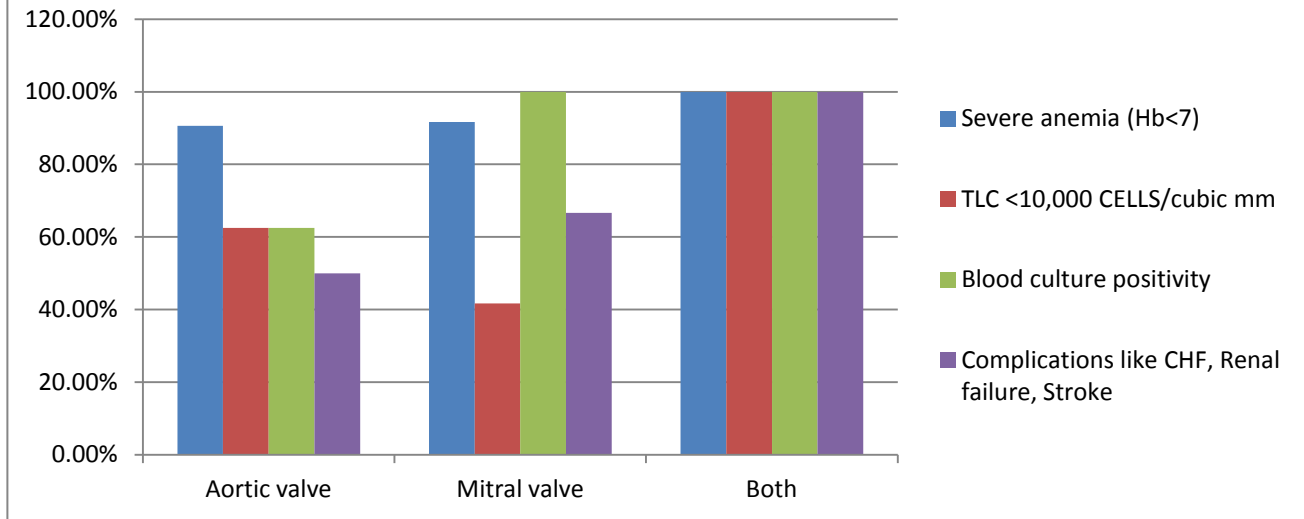
Figure 2: Signs of IE



On Echocardiography, 32 patients showed involvement of Aortic valve, and 12 patients showed involvement of the Mitral valve, only 1 patient showed the involvement of both Aortic and Mitral valves. The clinical findings in these three types of patients are shown in Figure 3. Out of the total no. of patients that showed valvular lesions on echocardiography (45 out of 52), 41 patients had severe anemia (Hb < 7 gm%).

Complications like Cardiac failure, Renal failure and Stroke were also very common among patients with valvular lesions. Staph aureus was the most common organism associated with valvular disease (40 out of 45) and only 2 patients were found to have streptococcus viridians as the causative organism. In the remaining 3 patients with positive 2D-Echo findings, the organism could not be isolated.

Figure 3: severity and complications associated valvular lesions



DISCUSSION

Our study shows that most of the patients of IE were in the age group of 11 to 20 years. Only 2 patients were in the age group of 51 to 60 years and only 3 were over 60 years of age. A similar study conducted by Sarkar et al in 2017 shows similar results with 44% of their subjects being in the age group of 10 to 20 years (7). These findings are very different from several different studies conducted in the west, that show that the mean age of patients has shifted up by several decades (8). The difference is possibly due to the fact that India is still a developing nation and that sanitation and healthcare are still not easily accessible. Also, the occurrence of Rheumatic disease is higher in India as compared to developed nations (9).

57.69% of patients in our study were males (30 out of 52), and remaining were females. Sarkar et al, in their study, showed a male to female ratio of 3.16:1, which shows male preponderance just like the present study (7). Several other studies conducted in India show similar results (9).

The patient of IE shows various signs and symptoms, which are although not diagnostic, but aid in considering IE as a differential diagnosis. Also, these correlate extremely well with the condition of the patient and the severity of the disease. In our study, we found that Fever was present in 100% of the patients. Similar results are shown in other studies (7). Pallor and cardiac murmurs are also predominant findings in IE patients in our study. Sarkar et al also demonstrate significant clinical findings in their subject samples (7).

Echocardiography has emerged as a boon in diagnosing Infective Endocarditis. It also localises the site of the lesion (detect which valve is involved) and is easy to use, quick, and relatively cheaper. In our study, echocardiography was used as a tool to understand the correlation between the involvement of different valves with the severity of the disease in terms of signs, symptoms, clinical findings and various complications. The present study shows that the Aortic valve was the most common valve involved in IE (32 patients) followed by the Mitral valve (12 patients). Only

one patient showed involvement of both the valves and tricuspid or pulmonary valve involvement was not shown. Sarkar et al found similar results in their studies with 32% patients showing lone Aortic valve involvement and 20% showing Mitral valve involvement (7).

In the present study, we tried to correlate the clinical severity of the patient with the findings on Echocardiography. The patients with lesion on Aortic valve lesion showed similar occurrence of severe anemia (Hb <7 gm%) as compared to patients with mitral valve lesion, but lower occurrence of complications like cardiac failure, liver failure and Stroke. It should however be noted that in our study, the relative incidence of Aortic valvular lesion is much higher compared to Mitral valve lesion. Only one patient in our study showed the involvement of both Aortic and Mitral valve, and that patient showed the presence of severe anemia, decreased TLC counts, blood culture positivity as well as all the aforementioned complications. It is clear from our study that if the Echocardiography shows the involvement of cardiac valves, the clinical picture is usually severe. In the study conducted by Sarkar et al, 88% of their patients show reduced haemoglobin. Other clinical findings also correlate with the presence or absence of valvular vegetations in their study (7). Certain western studies, however, don't show significant anaemia in their patients, and this could be due to the generalised malnutrition seen in Indian patients as compared to developed nations (10). Congestive Cardiac failure has been shown as a significant mortality and prognostic indicator in patients of Endocarditis in studies conducted in the west (11, 12).

In our study, we see Staph aureus as the predominant organism causing IE. Staph aureus seems to have replaced oral Streptococci as the most common organism causing IE as shown by

several studies (2, 3). This is confirmed by Sarkar et al in their study where they managed to isolate Staph aureus in 12% of their samples (7). Other Indian studies align with these findings (13). Now that the change in the etiology of IE has been clearly established, it should be possible to develop targeted Antibiotic therapies that consider the emerging pattern of resistance in Staph aureus.

CONCLUSION

Infective endocarditis (IE) is the infection of a native or prosthetic heart valve, the endocardial surface of heart, or an indwelling cardiac device. If the Echocardiography shows the involvement of cardiac valves, the clinical picture is usually severe. The change in pattern of the disease and the correlation of the clinical picture with the echocardiographic findings has been demonstrated without a doubt in our study.

REFERENCES

- 1) Cahill TJ, Prendergast BD: Infective endocarditis. *Lancet* 2016; 387(10021): 882-93.
- 2) Selton-Suty C, Célard M, Le Moing V, et al. Preeminence of Staphylococcus aureus in infective endocarditis: a 1-year population-based survey. *Clin Infect Dis.* 2012; 54(9): 1230-9.
- 3) Fowler VG, Miro JM, Hoen B, et al.: Staphylococcus aureus endocarditis: a consequence of medical progress. *JAMA* 2005; 293(24): 3012-21.
- 4) Baddour LM, Wilson WR, Bayer AS. Infective endocarditis: Diagnosis, antimicrobial therapy, and management of complications. A statement for healthcare professionals from the Committee on Rheumatic Fever, Endocarditis, and Kawasaki Disease, Council on Cardiovascular Disease in the Young, and the Councils on Clinical Cardiology, Stroke, and Cardiovascular Surgery and

Anesthesia, American Heart Association: endorsed by the Infectious Diseases Society of America. *Circulation* 2005; 111 (23): 394-434.

5) Banchs J, Yusuf SW. Echocardiographic evaluation of cardiac infection. *Expert Rev Cardiovasc Ther.* 2012;10 (1): 1-4.

6) Durack DT, Lukes AS, Bright DK. New criteria for diagnosis of infective endocarditis: Utilization of specific echocardiographic findings. *Am J Med.* 1994; 96: 200.

7) Sarkar A, Kumar P, Mukherjee S, Passi A, Singh JK. A study of clinical and etiological profile of infective endocarditis and its correlation with echocardiography in patients of rheumatic heart disease. *Int J Adv Med* 2017; 4:1323-7.

8) Baddour LM. Twelve-year review of recurrent native-valve infective endocarditis: A disease of the modern antibiotic era. *Rev Infect Dis.* 1988;10 (6): 1163- 70.

9) Chaudhary R. Active infective endocarditis observed in an Indian Hospital 1981-91. *Am J Cardiol.* 1992;70: 1453-8.

10) Murdoch DR, Corey GR, Hoen BL. Clinical presentation, etiology, and outcome of infective endocarditis in the 21st century. *Arch Intern Med.* 2009;169 (5): 463-73.

11) Sexton DJ, Spelman D. Current best practices and guidelines: assessment and management of complications in infective endocarditis. *Cardiol Clin.* 2003; 21: 273-282.

12) Mills J, Utley J, Abbott J. Heart failure in infective endocarditis: predisposing factors, course and treatment. *Chest* 1974; 66: 151–157.

13) Lopez J, Fernandez-Hidalgo N, Revilla A. Internal and external validation of a model to predict adverse outcomes in patients with left sided infective endocarditis. *Heart* 2011; 97 (14):1138-42.