

MORPHOLOGICAL DIVERSITY OF ENDOMETRIAL LESION IN WOMEN COMPLAINING ABNORMAL UTERINE BLEEDING

Dr. Sonal Agarwal^{1*}

1. Associate Professor, Department of Pathology, Geetanjali Medical College and Hospital, Udaipur

*Corresponding author – Dr. Sonal Agarwal

Email id – jsonal77@gmail.com

Received: 22/04/2020

Revised:18/05/2020

Accepted: 25/05/2020

ABSTRACT

Background: DUB is one of the common problems in females and has a huge impact on women's quality of life. It may represent a normal physiological state or can be a sign of a serious underlying condition endometrial carcinoma in 8-50% of cases. The present study is thus conducted to study the morphological spectrum of the endometrium which is essential for adequate treatment. **Material and Methods-:** The study was conducted in the Department of Pathology, Tertiary Care Center, Udaipur. 105 patients clinically diagnosed as DUB were included in this study over a period of five months. Endometrial samples were obtained from dilatation and curettage or endometrial biopsy. Specimens were received in 10% formalin. The gross morphology of the tissue samples was studied. **Result:** The most common age group (28.57%) affected was between the 4th and 5th decade which is the perimenopausal age group. The patients presented with various complaints but menorrhagia was the commonest bleeding pattern seen in 45 patients (42.86%). On categorising patients according to their parity, most of the females were multiparous (52.38%) while least was Nullipara (4.76%). On performing the histopathological examination, in a maximum of the patients with DUB, Endometrial hyperplasia (40%) was found. **Conclusion:** The endometrial patterns varied in cases of DUB ranging from normal endometrium to Atypia which is a pre-cancerous condition, thereby highlighting the importance of endometrial curetting and biopsy as a diagnostic procedure in the evaluation. Accurate analysis of endometrial samplings is, therefore, the key to effective therapy and optimal outcome.

Keywords: Uterus, Bleeding, Endometrial hyperplasia

INTRODUCTION

Dysfunctional uterine bleeding (DUB) is excessively heavy, prolonged, or frequent bleeding of uterine origin that is not related to pregnancy or any pelvic or systemic disease (1). DUB can occur any time between puberty to menopause and may be ovulatory or anovulatory. A history of excessive bleeding with regular menstrual cycles is usually associated with ovulation. An anovulatory pattern of bleeding is associated with intermenstrual bleeding, seen typically at puberty or in women in their mid-30s onwards (2). It is one of the common problems in females attending gynaecology OPD and has a huge impact on women's quality of life (3).

DUB is a diagnosis of exclusion. It may represent a normal physiological state or can be a sign of a serious underlying condition. Dysfunctional uterine

bleeding may be the symptom of endometrial carcinoma in 8-50% of cases (4). Detailed history, thorough physical examination, and appropriate investigation are the main tools to rule out the cause of bleeding (5).

Histopathological examination of endometrium in patients with DUB shows a wide spectrum of changes ranging from normal endometrium to hyperplasia, irregular reepithelialization, chronic menstrual irregular shedding, and atrophies (6). The management of DUB depends upon the type of endometrium found histopathologically. The present study is, thus, conducted to study the morphological spectrum of the endometrium which is essential for adequate treatment.

METHODOLOGY

The present study was conducted in the Department of Pathology, Tertiary Care Center, Udaipur. A total of 105 patients clinically diagnosed as DUB were included in this study during the period of five months. Detailed clinical history & general and systemic examination of the patients were recorded. Endometrial samples were obtained from dilatation and curettage or endometrial biopsy.

Specimens were received in 10% formalin. The gross morphology of the tissue samples was studied. The samples were studied grossly and were processed in an automated tissue processor. 5 μ thick paraffin-embedded serial sections were taken and stained by Haematoxylin and Eosin stain. Detailed microscopic examination was done in each case. The data was recorded and tabulated under relevant headings and thorough analysis was done.

Patients were categorized into reproductive age groups (18-40 yrs), perimenopausal (41-50), and postmenopausal (>50yrs).

Inclusion Criteria: Endometrial samples obtained from patients clinically diagnosed as DUB.

Exclusion Criteria: Patients presenting with bleeding due to pregnancy-related complications, organic lesions involving the genital tract infections, systemic causes, endometrial polyps, iatrogenic causes like intrauterine contraceptive devices & exogenous hormones like oral contraceptive pills.

RESULT

In the study, the minimum age of presentation of DUB was 19 years & the maximum age was 71 years. The most common age group (33.33%) affected was between 4th and 5th decade which is the perimenopausal age group followed by 31-40 years (28.57%) while the least was in > 70 years age group (1.90%) (Table1). Out of 105 females included in the study, 59 (56.19%) of the females were from urban areas.

On categorising patients according to their parity, most of the females were multiparous (52.38%) followed by Primipara (28.57%), Grand multipara (14.29%) & least was Nullipara (4.76%). (Figure 1)

The patients presented with various complaints but menorrhagia was the commonest bleeding pattern seen in 45 patients (42.86%) followed by Polymenorrhagia in patients 25 (23.81%). Metrorrhagia & hypomenorrhea was the least common bleeding pattern seen in 2 patients each (1.90%) (Table 2).

Table 1- Age-wise distribution of the patients

S.No	Age group (Years)	Number of patients (%)
1	≤20	3 (2.86%)
2	21-30	20 (19.05%)
3	31-40	30 (28.57%)
4	41-50	35 (33.33%)
5	51-60	11 (10.47%)
6	61-70	4(3.81%)
7	>70	2 (1.90%)
	Total	105 (100)

Table 2- Types of bleeding pattern seen in patients

S.No	Bleeding pattern	No. (%)
1	Menorrhagia	45 (42.86%)
2	Polymenorrhagia	25 (23.81%)
3	Polymenorrhoea	5 (4.76%)
4	Metrorrhagia	2 (1.90%)
5	Menometrorrhagia	4 (3.81%)
6	Oligomenorrhea	5 (4.76%)
8	Post menopausal	17 (16.19%)
9	Hypomenorrhoea	2 (1.90%)
	Total	105 (100)

On performing the histopathological examination of the endometrium tissue, it was found that in a maximum of the patients with DUB (28.57%), Simple Hyperplasia without Atypia was found. In the rest of the patients, Proliferative endometrium was seen in 20 (19.05%) patients followed by Irregular Ripening in 15 (14.29%), Secretory endometrium in 10 (9.52%), Irregular Shedding in 8

(7.62%), Simple Hyperplasia with Atypia in 7 (6.67%) patients.

Table 3- Endometrial pattern in DUB

S.No	Endometrial pattern	No. (%)
1	Proliferative endometrium	20 (19.05%)
2	Secretory endometrium	10 (9.52%)
3	Disordered Proliferative endometrium	5 (4.76%)
4	Irregular Ripening	15 (14.29%)
5	Irregular Shedding	8 (7.62%)
6	Atrophic endometrium	3 (2.86%)
8	Simple Hyperplasia without Atypia	30 (28.57%)
9	Simple Hyperplasia with Atypia	7 (6.67%)
10	Complex Hyperplasia without Atypia	4 (3.81%)
11	Complex Hyperplasia with Atypia	1 (0.95%)
12	No interpretation (Scanty Material)	2 (1.90%)
	Total	105 (100%)

The less common findings were Disordered Proliferative endometrium that was seen in 5 (4.76%) patients, Complex Hyperplasia without Atypia seen in 4 (3.81%) patients, Atrophic endometrium present in 3 (2.86%) patients, and Complex Hyperplasia with Atypia seen only in 1 (0.95%) patient. (Table 3)

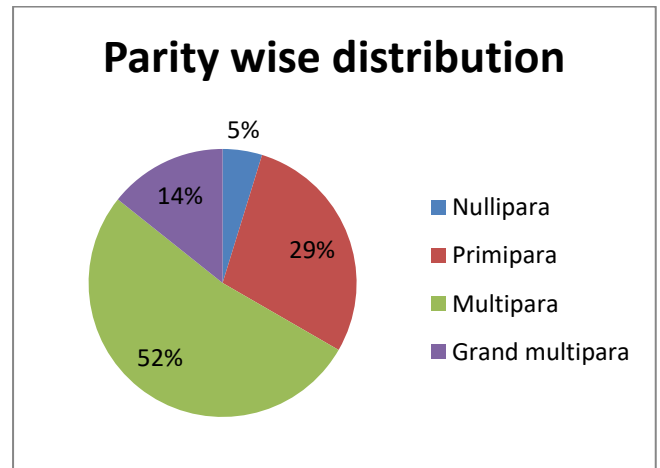


Fig 1 Showing Parity wise distribution

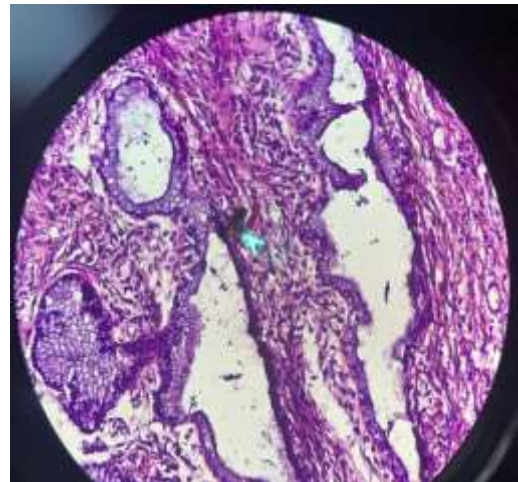


Fig.2. Proliferative phase of endometrium

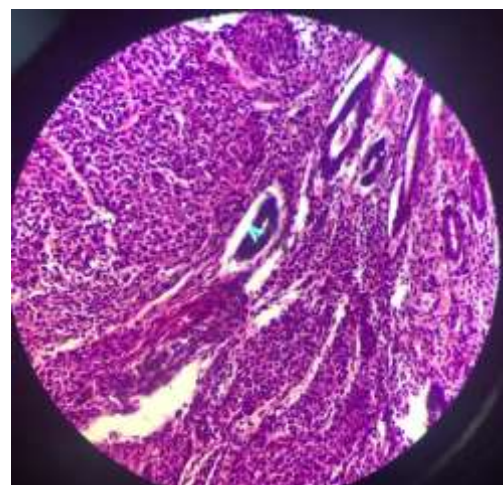


Fig.3. Chronic Endometritis

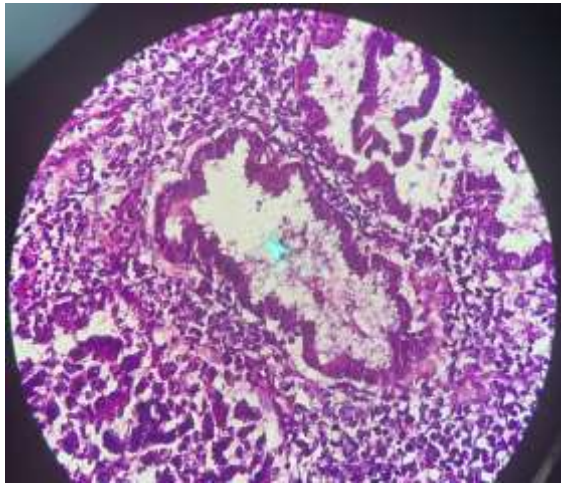


Fig.3. Secretory phase of endometrium

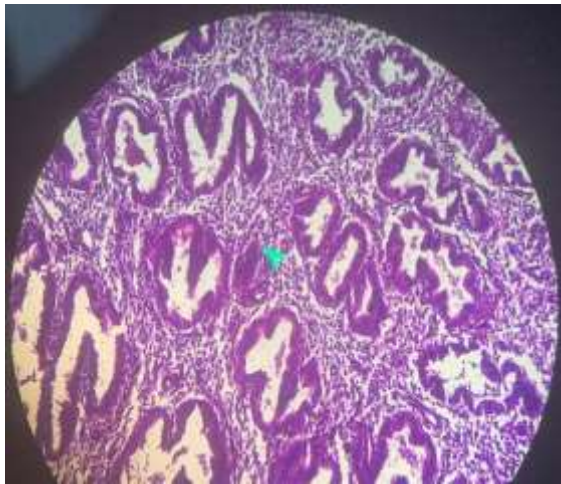


Fig.4. Simple hyperplasia without atypia

DISCUSSION

In DUB abnormalities along the hypothalamic-pituitary-ovarian axis may result in derangements of follicular maturation, ovulation, or corpus luteum formation resulting in hormonal changes. These changes may lead to abnormal uterine bleeding⁷. The present study was done to evaluate the histopathology of endometrium in females clinically diagnosed as DUB. In this study, 105 such females attending OPD during the period of five months were included.

The most likely etiology of DUB relates to the patient's age as to whether the patient is premenstrual, menstrual, or postmenopausal (8). In our study, the age group range from 19-71 years. The most common age group (33.33%) affected was between 4th and 5th decade which is the perimenopausal age group followed by 31-40 years

(28.57%) while the least was in > 70 years age group (1.90%). This was similar to the study done by Sharma et al who reported in their study that maximum patients of DUB were in the age group 41-50 years (9).

On categorising patients according to their parity in our study, most of the females were multiparous (52.38%) while least was Nullipara (4.76%). This was similar to the study done by A Fatima, where 71.83% were multiparous females who complained of DUB (10).

In this study, menorrhagia was the commonest bleeding pattern seen in 45 patients (42.86%) & Metrorrhagia & hypomenorrhea was the least common bleeding pattern seen in 2 patients each (1.90%). This was in coherence with the study done by Jetley et al, who revealed that the most common clinical presentation was represented by menorrhagia (46.4%) (11). R Khan et al. also reported that the most common presenting complaint in their study was menorrhagia (55.8%) & hypomenorrhea for the least common complaint (1.60%) (12).

On histopathological examination of the endometrium tissue in this study, it was found that in a maximum of the patients with DUB (40 %), Endometrial Hyperplasia was found followed by Proliferative endometrium which was seen in 20 (19.05%) patients. In cases with hyperplasia, Simple Hyperplasia without Atypia was present in 28.57% cases, followed by Simple Hyperplasia with Atypia (6.67%), Complex Hyperplasia without Atypia (3.81%). Complex Hyperplasia with Atypia (0.95%) was the least common endometrial pattern detected in DUB.

These results were almost similar to the study conducted by A Fatima et al in which Endometrial hyperplasia was the commonest pattern seen in 46.47% of patients (10). Pilli GS et al & Rajesh Patil et al also in their study revealed (13,14) that endometrial hyperplasia was the commonest finding. In the study conducted by Sharma et al⁹ more than half of the histomorphological reported cases of endometrial hyperplasia showed simple hyperplasia whereas only 1.09% cases showed complex hyperplasia with atypia (9).

In the current study, Proliferative endometrium was the next common finding which was seen in 19.05% of patients. This was in concordance with the study done by Bhoomika Dadhania et al (15) in which 21% reported Proliferative endometrium. Irregular ripening was seen in 14.29% of the females in the

present study while in the study done by R Khan et al irregular ripening was present only in 3.33%. (12)

In 9.52% of the patients in the present study, Secretory endometrium was found which was similar to a study done by A Fatima et al in which 10.21% showed Secretory endometrium on examination (10).

In the present study, 4.76 % of the patients showed Disordered Proliferative endometrium on examination. This was almost similar to results shown by A Fatima et al in which 4.93% of cases showed a similar endometrium pattern (10).

This current study showed that in 2.86% of the patients atrophic endometrium was seen which was almost in concordance with the study done by R Khan et al in which 3.33% showed atrophic endometrium on histopathological examination. (12).

Irregular shredding in the present study was seen in 7.62% of patients, while Pilli GS et al in their study showed that only 2% of the cases revealed irregular shredding. (13).

CONCLUSION

Dysfunctional uterine bleeding is a common problem in females, especially in the perimenopausal age group. The endometrial patterns varied in cases of DUB ranging from normal endometrium to Atypia which is a pre-cancerous condition, thereby highlighting the importance of endometrial curetting and biopsy as a diagnostic procedure in the evaluation. Accurate analysis of endometrial samplings is, therefore, the key to effective therapy and optimal outcome.

REFERENCES

1. Livingstone M, Fraser IS. Mechanisms of abnormal uterine bleeding. *Hum Reprod Update*. 2002 Jan-Feb;8(1):60-7. doi: 10.1093/humupd/8.1.60.
2. Farrell E. Dysfunctional uterine bleeding. *Aust Fam Physician*. 2004 Nov;33(11):906-8.
3. Abnormal uterine bleeding | National Health Portal of India [Internet]. Nhp.gov.in. 2021 [cited 31 December 2021]. Available from: <https://www.nhp.gov.in/disease/gynaecology-and-obstetrics/abnormal-uterine-bleeding>
4. Dangal G: A study of endometrium in patients with abnormal uterine bleeding at Chitwan valley. *Kathmandu University Medical Journal*, 2003;1(2):110- 112.

5. Bongers MY, Mol BW, Brolmann HA. Current treatment of dysfunctional uterine bleeding. *Maturitas* 2004;47:159–174.

6. Sutherland AM. Functional uterine hemorrhage: a critical review of the literature since 1938. *Glasgow Med J*. 1949;30:1–28.

7. Munro MG, Critchley HO, Broder MS, Fraser IS. FIGO classification system (PALM-COEIN) for causes of abnormal uterine bleeding in nonpregnant women of reproductive age. *Int J Gynaecol Obstet*. 2011;113:3–13.

8. Dhlenbach-Hellweg G. *Histopathology of endometrium*. 4th ed. New York: Springer-Verlag; 1993.

9. Sharma R., Mishra P., Kumar N., Srivastava P. Histomorphological spectrum of endometrial lesion in women presenting with abnormal uterine bleeding: A 3-year study at a tertiary care center. *Trop J Path Micro* 2018;4(7):525- 531.

10. Fatima A, Dombale V.D. Morphological Spectrum of Endometrium in Dysfunctional Uterine Bleeding. *Indian Journal of Pathology: Research and Practice*. 2017; 6 (2): 349-353.

11. Jetley S, Rana S, Jairajpuri ZS. Morphological spectrum of endometrial pathology in middle-aged women with atypical uterine bleeding: A study of 219 cases. *J Midlife Health*. 2013 Oct;4(4):216-20.

12. Khan R, Sherwani RK, Rana S, Hakim S, S Jairajpuri Z. Clinico-Pathological Patterns in Women with Dysfunctional Uterine Bleeding. *Iran J Pathol*. 2016 Winter;11(1):20-6.

13. Pilli GS, Sethi B, Dhaded AV, Mathur PR. Dysfunctional uterine bleeding – A study of 100 cases. *J Obstet Gynecol India* 2002 May-Jun; 52(3):87-89.

14. Patil R, Patil RK, Andola SK, Laheru V, Bhandar M. Histopathological spectrum of endometrium in dysfunctional uterine bleeding. *Int J Biol Med Res* 2013; 4(1):2798-801.

How to cite this article: Agarwal S., Morphological diversity of endometrial lesion in women complaining abnormal uterine bleeding. *Int.J.Med.Sci.Educ* May-June. 2020; 7(3):38-42