

VISUAL OUTCOME IN PATIENTS WITH INDIRECT TRAUMATIC OPTIC NEUROPATHY(TON) RECEIVING TIMELY INTERVENTION WITH METHYL PREDNISOLONE IN A TERTIARY CARE HOSPITAL OF SOUTHERN RAJASTHAN

Dr Nutan Bedi¹, Dr Saloni Patel^{2*}

1. Associate Professor, 2. P.G. Resident, Department of Ophthalmology, Geetanjali Medical College and Hospital, Udaipur

*Corresponding author – Dr Saloni Patel

Email id – saa41192@gmail.com

Received:22/11/2019

Revised:20/12/2019

Accepted:04/01/2020

ABSTRACT

Background: The incidence of traumatic optic neuropathy has shot up due to rapid increase in the number of vehicles on road. TON occurs in head or ocular trauma and endangers vision either due to direct or indirect injury to the optic nerve. Direct injury can be by sharp objects or displaced bony spicules. It may also result into optic nerve avulsion **Material & Methods:** The prospective study was conducted in 53 patients diagnosed with indirect TON who presented to the outpatient ophthalmology department of a tertiary care hospital in Southern Rajasthan. The study was undertaken in patients diagnosed with indirect TON and treated with methylprednisolone. **Results:** The pretreatment vision was ranging from 6/12 to 6/36 in 5 patients and 6/60 to CFCF in 14 patients. 34 cases had visual acuity between HM to NOPL. Total 36(67.92%) out of 53 patients had shown improvement in visual acuity after treatment in which patients who were given treatment with methylprednisolone within 24 hours(52.8%) of diagnosis had shown maximum improvement in vision followed by those in whom treatment was started within 72 hours(22.6%). Patients with delayed presentation between 1 week to 2 weeks had no improvement in vision, out of which ≥ 3 line improvement was found in 30 patients (60.3%). **Conclusion:** We concluded from the present study that our study emphasizes the use of high dose methylprednisolone for indirect TON to decrease the ocular morbidity to a considerable extent specially if the patients report within 24 to 72 hours.

Key words: Retinal degenerations, Retinal detachment, Lattice degeneration.

INTRODUCTION

The incidence of traumatic optic neuropathy has shot up due to rapid increase in the number of vehicles on road.(1) TON occurs in head or ocular trauma and endangers vision either due to direct or indirect injury to the optic nerve.(2) Direct injury can be by sharp objects or displaced bony spicules. It may also result into optic nerve avulsion.(3) Indirect TON is due to reactionary edema in the sheath around optic nerve causing compressive optic neuropathy. Hemorrhages and edema in tight optic canal also contribute to optic nerve damage. This is because the

vascular supply to retinal ganglion cells gets compromised leading to retrograde degeneration of ganglion cells. (4)

In indirect TON, the most common site of injury is intracranial optic nerve followed by intracranial course of optic nerve.(2) TON causes considerable visual loss which if diagnosed and treated promptly can give rewarding results.(4) Role of corticosteroids has been found to be significant since it reduces inflammation and edema in the restricted space of

the optic canal which prevents secondary compressive optic neuropathy and also prevents free radical injury by lipid peroxidation thus providing neuroprotection.(1) we conduct the present study to assess the visual outcome in patients with indirect traumatic optic neuropathy (ton) receiving timely intervention with methyl prednisolone in a tertiary care hospital of southern Rajasthan.

MATERIALS & METHODS

The prospective study was conducted in 53 patients diagnosed with indirect TON who presented to the outpatient ophthalmology department of a tertiary care hospital in Southern Rajasthan. The study was undertaken in patients diagnosed with indirect TON and treated with methylprednisolone. Study was conducted at 95% confidence interval at 5% of maximum allowable error. Patients who were diagnosed clinically were enrolled by simple random sampling and randomized. Clearance from hospital ethics committee was taken before start of study. Written informed consent was taken from each study participant.

All the data were recorded related to detailed clinical history, cause of admission and co-morbidities. Direct TON cases and patients in whom use of methylprednisolone was neurologically contraindicated were excluded. Each patient was examined thoroughly, examination included: Visual acuity, color vision, pupillary reaction (direct and consensual), IOP, Optic disc evaluation (Direct and indirect ophthalmoscopy), OCT RNFL, Automated visual field testing in patients with visual acuity more than CF3m and Radiological investigations (CT/MRI Brain & Orbit). Patients diagnosed with TON weretreated with 1gm intravenous methylprednisolone for 3 days followed by oral prednisolone 1mg/kg for 10 days and the patients were observed over several days for improvement in vision.. Data analysis was carried out using SPSS v22. All tests were done at alpha (level significance) of 5%; means a significant association present if p value was less than 0.05.

RESULTS

The present study was undertaken in 53 study participants. Out of the total study participants 53

patients 43 patients were males and 10 patients were female. 31-40 years of age group were commonly involved accounting for 45.28% of study population. The most common cause of indirect TON was motor vehicle accident (69.81%) followed by blunt trauma (16.98%), fall (11.32%) and assault (1.88%). (Table 1)

Table 1: Distribution of study participants according to cause of optic neuropathy.

Cause	No. of pts	Percentage (n=53)
Motor vehicle accident	37	69.81%
Fall from height	06	11.32%
Blunt trauma	09	16.98%
Assault	01	1.88%

Out of the total study participants 53 patients the most common cause of indirect TON was motor vehicle accident (69.81%) followed by blunt trauma (16.98%), fall (11.32%) and assault (1.88%).

Table 2: Distribution according to baseline visual acuity at the time of presentation.

Base line VA	no of pts	Percentage (n=53)
6/6-6/9	0	-
6/12-6/18	01	1.88%
6/24-6/36	04	7.54%
6/60	05	9.43%
<6/60- CFCF	09	16.98%
HM	18	33.96%
PL	11	20.75%
NOPL	05	9.43%

The pretreatment vision was ranging from 6/12 to 6/36 in 5 patients and 6/60 to CFCF in 14 patients. 34 cases had visual acuity between HM to NOPL. Total 36(67.92%) out of 53 patients had shown improvement in visual acuity after treatment in which patients who were given treatment with

methylprednisolone within 24 hours(52.8%) of diagnosis had shown maximum improvement in vision followed by those in whom treatment was started within 72 hours(22.6%). Patients with delayed presentation between 1 week to 2 weeks had no improvement in vision, out of which ≥ 3 line improvement was found in 30 patients (60.3%).

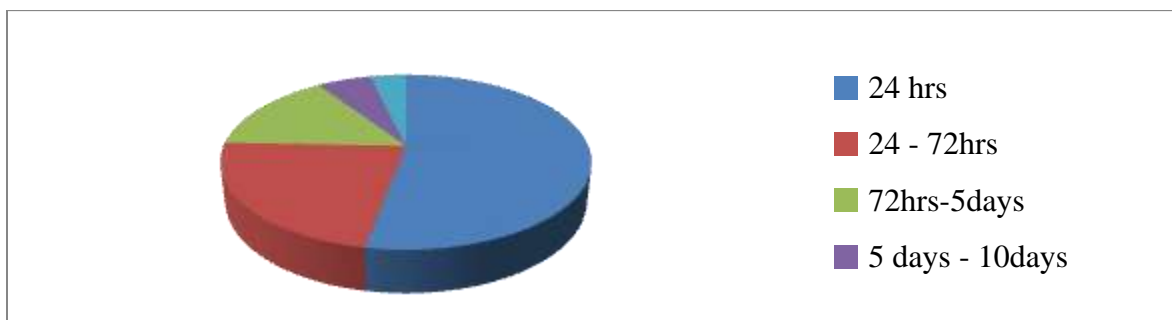
19 Patients had baseline visual acuity CF or better in which ≥ 3 line improvement after treatment was

noticed in 14 cases(73.6%).34 Patients had baseline visual acuity HM,PL and NOPL before treatment out of which only 16(47%) had ≥ 3 line improvement after treatment. The patients were followed-up for 1 month. Maximum visual improvement was seen immediately after treatment (75%) followed by 2nd day to within 1 week (19.44%). In the follow-up between 1 to 3 weeks only 2(5.55%) patients were noticed to have vision improvement.

Table 3: Distribution according to initiation of treatment and outcome observed over 3 week.

Initiation of treatment with methyl prednisolone within	Total No . of pts (n=53)	No. of pts with significant improvement in vision after treatment	No. of pt with NO improvement after treatment
24 hours	28 (52.8%)	24 (85.7%)	4
24-72 hours	12 (22.6%)	8 (66.6%)	4
72hrs- 5days	08 (15%)	3 (37.5%)	5
5days-10days	03 (5.6%)	1 (33.3%)	2
10days -15days	02 (3.7%)	-	2

Figure 1 .Initiation of treatment with methylprednisolone in cases of indirect TON



DISCUSSION

Indirect optic neuropathy was found to be a common cause of blindness in cases of RTA. Motor vehicle accidents (69.8%) were the main reason for indirect TON followed by blunt trauma (16.98%), fall (11.32%) and assault (1.88%) which is consistent with Rajendra Chaudhary study. (5) Majority of the patients were in the age group of 21-40 years which is consistent with Rajinganth et al (6) and Entezari et al (7). This is due to the rash driving prevalent amongst youngsters and needs to be addressed

firmly so that safe driving is strictly observed as a precautionary measure.

The pretreatment vision was ranging from 6/12 to 6/36 in 5 patients and 6/60 to CFCF in 14 patients. 34 cases had visual acuity between HM to NOPL. Total 36(67.92%) out of 53 patients had shown improvement in visual acuity after treatment in which patients who were given treatment with methylprednisolone within 24 hours (52.8%) of diagnosis had shown maximum improvement in vision followed by those in whom treatment was started within 72 hours (22.6%). Patients with

delayed presentation between 1 week to 2 weeks had no improvement in vision, out of which ≥ 3 line improvement was found in 30 patients (60.3%).

19 Patients had baseline visual acuity CF or better in which ≥ 3 line improvement after treatment was noticed in 14 cases (73.6%).

34 Patients had baseline visual acuity HM, PL and NOPL before treatment out of which only 16 (47%) had ≥ 3 line improvement after treatment. The patients were followed-up for 1 month.

Maximum visual improvement was seen immediately after treatment (75%) followed by 2nd day to within 1 week (19.44%). In the follow-up between 1 to 3 weeks only 2 (5.55%) patients were noticed to have vision improvement.

For treatment of indirect TON, many studies have been conducted which included IV methylprednisolone, optic nerve decompression surgery and merely observation (8). But our study included use of high dose of IV methylprednisolone followed by oral prednisolone for 10 days and we noticed that there was a drastic improvement in those patients who received the above regimen within 24 hours although the patients who came within 72 hours also showed satisfactory visual improvement which is consistent with Rohit Saxena study (9).

CONCLUSION

We concluded from the present study that our study emphasizes the use of high dose methylprednisolone for indirect TON to decrease the ocular morbidity to a considerable extent specially if the patients report within 24 to 72 hours.

REFERENCES

1. Rohit S, Digvijaya s, Vimala M. Controversies in neuro-ophthalmology: steroid therapy for traumatic optic neuropathy. Indian journal of Ophthalmology 2014;62(10):1028-30.
2. Crompton MR. Visual lesions in closed head injury. Brain 1970;93(4):785-92.
3. Nazir SA, Westfall CT, Chacko JG, Philips PH et al. Visual recovery after direct traumatic optic neuropathy. 2010;31:193-1.
4. Alexandra BC, Victoria V, Melissa LC, Sarah AN et al. Front neurosci. 2019;13:179
5. Guyer DR Miller NRL Long DM Allen GS Visual function following optic canal decompression via craniotomy. J Neurosurg. 1985;62:631-637. PubMedGoogle Scholar
6. Sewall EC External operation on the ethmosphenoid-frontal group of sinuses under local anesthesia. Arch Otolaryngol. 1926;4:377-411. Google Scholar
7. Kennerdel JS Amsbaugh GA Myers EN Transantral-ethmoidal decompression of optic canal fracture. Arch Ophthalmol. 1976;94:1040-1043. PubMedGoogle Scholar
8. Knox BE Gates GA Berry SM Optic nerve decompression via the lateral facial approach. Laryngoscope. 1990;100:458-462. PubMedGoogle Scholar
9. Chow JM Stankiewicz JA Powered instrumentation in orbital and optic nerve decompression. Otolaryngol Clin North Am. 1997;30:467-478. PubMedGoogle Scholar

How to cite this article: Bedi N., Patel S., Visual outcome in patients with indirect traumatic optic neuropathy(ton) receiving timely intervention with methyl prednisolone in a tertiary care hospital of southern rajasthan. Int.J.Med.Sci.Educ 2020;7(1):27-30