

POST TRAUMATIC TRIFID CONDYLE WITH TEMPOROMANDIBULAR JOINT ANKYLOSIS: A CASE REPORT

Dr. Divya Rana^{1*}, Dr. Harshdeep Dhaliwal²

1,2.Resident, Mahatma Gandhi Dental College & Hospital, Jaipur

*Email id of corresponding author- drdivyasrana@gmail.com

Received: 02/06/2016

Revised: 06/12/2016

Accepted: 15/12/2016

ABSTRACT

Trifid mandible condyle is an exceedingly rare entity with only 8 cases reported to date. The aetiology of the disorder is unknown, though like bifid mandibular condyle, a correlation with prior trauma is usually seen. We present a unique case of a 17-year-old male who presented with restriction of movements at the temporomandibular joint, with a history of trauma 10 years back. Imaging revealed unilateral temporomandibular joint ankylosis with trifid condyle.

KEYWORDS: Temporomandibular joint ankylosis, Trifid condyle.

INTRODUCTION:

The first case of trifid mandibular condyle was reported in the literature in 2003¹ and it is an exceptionally rare entity, the etiology and pathogenesis of which is not fully understood.¹⁻⁸ However, previous trauma to the TMJ region, congenital and developmental origins has both been suggested.^{1,2,4,5,7,8,9}

This developmental anomaly is usually asymptomatic, making it most likely to be an incidental finding during radiographic examination of the head and neck. However, some cases are found in patients with temporomandibular joint clicking, ankylosis, asymmetry of the face with nearly normal or restricted TMJ function.¹⁻¹⁰

Temporomandibular joint (TMJ) ankylosis is a pathological change with bony or fibrous ankylosis with deformity of the articular fossa and mild or severe formation of osseous tissue, impairing functions, such as speech, chewing, and mouth opening. This condition could be consequence of trauma, infection or degenerative changes. When ankylosis occurs during the childhood, the patient could show severe facial alterations.^{11,12}

Reported cases of bifid and trifid condyle in living individuals and dried specimens, are mostly unilateral.^{1-11, 13} The morphology of the bifidity and trifidity ranges from grooving to discrete condylar heads. Trifid mandibular condyle has three distinct heads.¹ The condyle appears abnormal on panoramic radiograph, therefore CT is essential for definitive diagnosis as it gives more accurate and specific picture of the pathology.^{1,3} This paper reports a case of unilateral trifid mandibular condyle with fibrous ankylosis in a 17-year-old male.

CASE REPORT

A 17 year-old man reported with a chief complaint of restricted mouth opening along with deviation on opening and facial asymmetry.(Figure 1) He revealed a history of trauma to chin during early childhood, 10 years back and was given stitches for chin lacerations. There was no history of pain and swelling subsequent to the trauma. The patient started noticing gradual and progressive restriction and deviation in mouth opening over the last two year. The inter incisal mouth opening was 22

mm at the time of inspection. On palpation, normal TMJ movements were felt on the left side but restricted movement of the condyle on the right side, along with restricted protrusive or lateral movement. No pain or joint sounds were elicited. His face presented signs of asymmetry with fullness of face on the right side, distinct deviation of chin, concavity of lower border of mandible, prominent antegonial notch, and decreased height of ramus on the right side.

Intraoral examination revealed midline shift towards the right along with class 2 molar relation.

Panoramic view (figure 2) revealed abnormally large and ill-defined condyle on the right side along with reduced joint space and obliteration on the posterior aspect of mandibular fossa along with flattening to accommodate the large condyle. TMJ open view showed restricted condylar translation on the right side.

In coronal sections,(figure 3) two shallow notches in the middle part of the condyle were observed, giving the appearance of trifid condyle mediolaterally. The axial view (figure 4) revealed three separate heads of the right condyle. On 3-D construction (figure 5) of the CT images, the right mandibular condyle appeared as trifid, having first and second heads situated mediolaterally and a third anteroposteriorly. The first and second heads were divided by a deep groove on the articulating surface. A third separate process, originating from below these two heads, was short and projected superiorly and posteriorly. Further, it was observed that the neck of the right mandibular condyle was short, and the ramus height on the right side was found to be less than that on the left side. The CT images confirmed the hypertrophy of the masseter muscle on the same side. Also, the joint space was reduced on the right side along with surface irregularities of the articulating surfaces of the condyle and the mandibular fossa indicating fibrous ankylosis of the right joint. No abnormality was observed on the CT images of the left mandibular condyle.

DISCUSSION

According to the literature at least 50 cases of bifid mandibular condyles and 8 cases of trifid condyles,¹⁻¹¹ and 1 patient of tetrafid condyle¹⁴ in living patients have been reported so far. This number has suddenly increased probably as a result of improved imaging techniques. In spite of this, the disorder is still considered rare.¹⁰

Artvinli¹, et al was the first to report such a case in 2003. Later, 7 cases of trifid condyle were reported: Antonides², et al, in 2004 Cagirankaya³, et al in 2005 ; Sezgun S⁴ et al in 2009 Warhekar⁵ et al in 2010 ; and Rodrigo millas⁶ et al in 2010 ; Jha A⁷ et al in 2013 and . TR Prasanna⁸ et al in 2015. The ages of the individuals ranged from 6 to 52 years, with a male to female ratio of 1:3.¹⁻⁸

The etiology of trifid condyle is not clearly known. Two out of three cases have a history of trauma to the facial region.¹⁻⁸ The present case also had a history of trauma at seven years of age. Thomason & Yusuf reported cases related to condyle fracture post-trauma, which, after healing, eventually led to bifid condyle formation.¹⁵ However, some post-traumatic bifid condyle cases are found in patients with TMJ symptoms, hypoplastic condyle or ankylosis.^{6-9,11,15,16} Stadnicki (1971) reported a case of a 3-year-old girl with limited mouth opening and a bifid condyle following forceps delivery, and the girl subsequently developed ankylosis at the age of 12 years.⁹

Zhi Li et al supported the opinion that posttraumatic bifid condyle develops in cases with insufficient remodelling capacity. After condylar trauma or fracture resulting in the condyle dividing into two major parts, the major bony fragment and the condyle stump, sufficient healing and remodelling processes might produce the two parts unite together and form one new condyle. Otherwise, the insufficient remodelling of the condylar bony fragment might give rise to the bifid condyle formation. However, it has also been stated that insufficient remodelling capacity is not the only contributing

factor in the formation of post-traumatic bifid condyle.¹⁶

Szentpétery, et al., suggested that the orientation of the condyle head could be related to probable cause. In cases where the orientation is anteroposterior, early childhood fractures are implicated, whereas in those cases with mediolaterally situated heads, the persistence of septa is suggested as a possible cause.¹⁷ While this may be true for the majority of cases, some mediolateral bifid condyles have been reported following sagittal fracture through the condylar head and condylar neck fracture.¹⁸

On the other hand, the radiographic appearance of TMJ ankylosis is widely variable with many features. Panoramic views shows the joint deformity, with loss of the joint space, irregularities of the articulating surfaces and abnormal bone formation in/or around the joint, but does not reveal the nature and the extent of the pathology, in relation to surrounding vital structures. Therefore, making Computed tomography (CT) the choice of imaging for the osseous pathologies of the temporomandibular joint as CT allows better visualization without superimposition of TMJ ankylosis.⁸ Three-dimensional CT reconstructed images enable the radiologist to visualize the condyle and its relationship with the base of the skull and surrounding structures, as well as to manipulate the image data quickly.^{7, 11, 18.}

The treatment of the symptomatic bifid condyle associated with limited mouth opening and ankylosis requires surgical intervention.^{9, 19, and 20.} There are three basic techniques for surgical correction of temporomandibular ankylosis: gap arthroplasty, interpositional arthroplasty and joint reconstruction.^{9, 19.} In the asymptomatic cases, the treatment is usually conservative and similar to the treatment for the closely associated TMJ pain dysfunction syndrome (analgesics and anti-inflammatory agents, muscle relaxants, physiotherapy, splint) and so the patients must be controlled and followed-up.^{1,9,19,20}

In the present case, the patient recalled a trauma to the chin in childhood at the age of 7 years which could have caused trauma to TMJ region. Whether there was a condyle fracture or not is unknown. Thus, the trifid mandibular condyle may have resulted from the abnormal condylar remodelling following trauma. Even though there is no image record previous to that time to assure the association, this account cannot be disregarded. The patient complaints were reduced and deviated mouth opening along with facial asymmetry. And in our opinion, the use of CT scan showed to be more advantageous than other imaging methods and provided great visualization of TMJ pathology and a correct diagnosis.

The association between TMC and TMJ ankylosis is rare and must be carefully evaluated. Also, because of absence of clinical symptomatology in the majority of the cases of bifid/trifid mandibular condyle, its diagnosis usually relies on radiological rather than clinical evidence. Therefore, the clinician and radiologist must be aware of this abnormality and of its implication on functional and morphological changes.

REFERENCES

1. Artvinli LB, Kansu O: Trifid mandibular condyle: a case report: Oral Surg Oral Med Oral Pathol Oral Radiol Endod; 95: 251 -254.
2. Antoniadis K, Hadjipetrou L, Antoniadis V: Bilateral bifid mandibular condyle. Oral Surg Oral Med Oral Pathol Oral Radiol Endod 2004; 97: 535Y538.
3. Cagrankaya LB, Hatipoglu MG. Trifid mandibular condyle: a case report. J Craniomandibular Pract 2005; 23:297Y299.
4. Sezgin ÖS, Kayipmaz S. Trifid mandibular condyle. Oral Radiol 2009; 25:146-8.

5. Warhekar AM, Wanjari PV, Phulambrikar T: Unilateral trifid mandibular condyle: A case report. *Cranio* 2011; 29:80-4.
6. TM Rodrigo Millas M(1), Jorge Cajas M(1), Drs. María Elena Causa U(2), Iván Melo G(1), Miguel Casals R(1), Lilian. Condilos Bifido Trifido En Disfuncion De La Articulacion Temporo Mandibular: Reporte De Dos Casos Clinicos. *Revista Chilena de Radiología*. Vol. 16 No 4, año 2010; 169-174.
7. Jha A, Khalid M, Sahoo B: Post traumatic bifid and trifid mandibular condyle with bilateral temporomandibular joint ankylosis. *J Craniofac Surg* 2013; 24:e166-7.
8. TR Prasanna, Suhas Setty¹, V Vadiraj Udupa, DS Sahana: Bilateral condylar anomaly: A case report and review. *Journal of Oral and Maxillofacial Pathology* Vol. 19 Issue 3 Sep - Dec 2015.
9. Stadnicki G: Congenital double condyle of the mandible causing temporomandibular joint ankylosis: report of case. *J Oral Surg* 1971; 29: 208-211.
10. José López-López, Raúl Ayuso-Montero, Enric Jané Salas, Xavier Roselló-Llabrés: Bifid Condyle-Review of the Literature of the Last 10 Years and Report of Two Cases: *The Journal of Craniomandibular Practice*: April 2010, VOL. 28, NO. 2.
11. Marcelo Augusto Oliveira SALES, Jefferson Xavier OLIVEIRA, Marcelo Gusmão Paraíso CAVALCANTI: Computed Tomography Imaging Findings of Simultaneous Bifid Mandibular Condyle and Temporomandibular Joint Ankylosis: Case Report; *Braz Dent J* (2007)18(1): 74-77.
12. Manganello-Souza LC, Mariani PB: Temporomandibular joint ankylosis: report of 14 cases: *Int J Oral Maxillofac Surg* 2003; 32:24-29.
13. Hrdlicka A: Lower jaw- double condyles: *Am. J. Phys. Anthop*, 28:75-89, 1941.
14. H S Ahman, OA Eto^{z2}, AE S,ekercil, M Eto^{z1} and Y S: Tetrafid mandibular condyle: a unique case report and review of the literature: *Dentomaxillofacial Radiology* (2011) 40, 524-530, 2011.
15. Thomason J. M. & Yusuf H: Traumatically induced bifid mandibular condyle: report of two cases. *Br. Dent. J.*, 161(8): 291-3, 1986.
16. Zhi Li¹, Kamardine Ahmed Djae, Zu-Bing Li: Post-traumatic bifid condyle: The pathogenesis analysis *Dental Traumatology* 2011; 27: 452-454.
17. Szentpetery A, Kocsis G, Marcsik A: The problem of the bifid mandibular condyle: *J Oral Maxillofac Surg* 1990; 48:1254-1257.
18. Daniels, J. S. & Ali: Post-traumatic bifid condyle associated with temporomandibular joint ankylosis: Report of a case and review of the literature. *Oral Surg Oral Med Oral Pathol Oral Radiol. Endod*, 99(6): 682-8, 2005.
19. To EWH. Mandibular ankylosis associated with a bifid condyle. *J Craniomaxillofac Surg* 1989; 17: 326-328.
20. Kansu O, Önerci M, Kansu H, Uysal S, Eryilmaz M. Bifid mandibular condyle associated with mandibular ankylosis: a case report. *J Turkish Oral Maxillofacial Surg* 1997; 1:54-7.

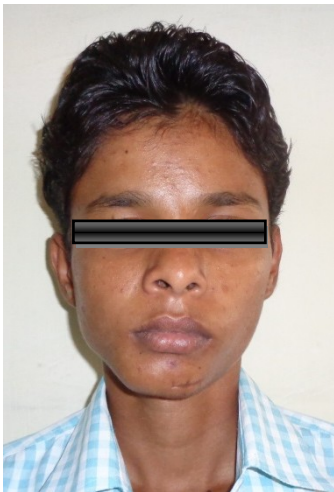

Figure 1.

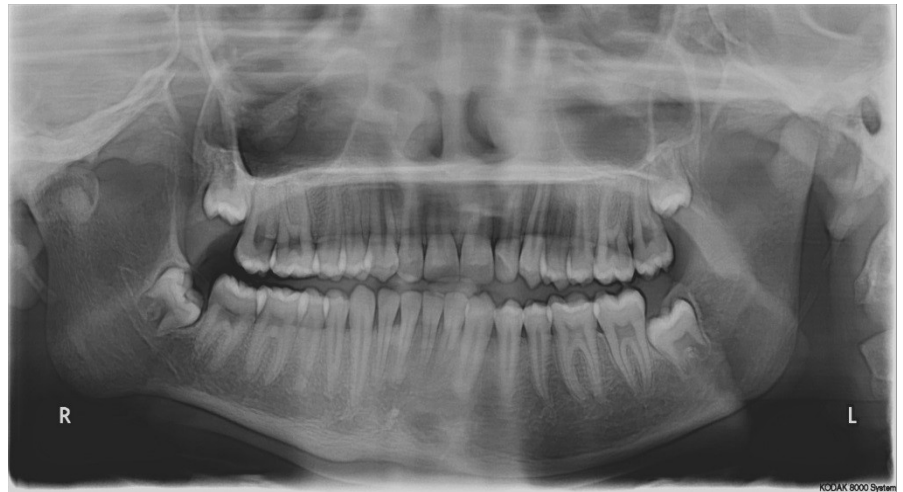

Figure 2.

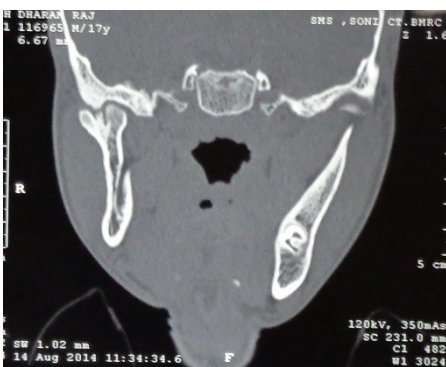

Figure 3.

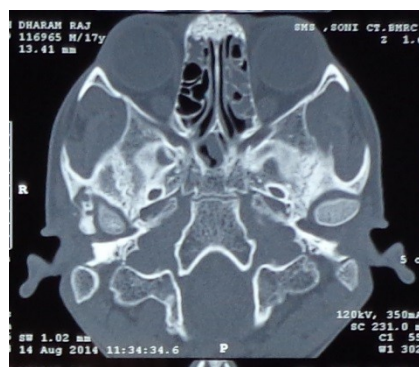


Figure 4.

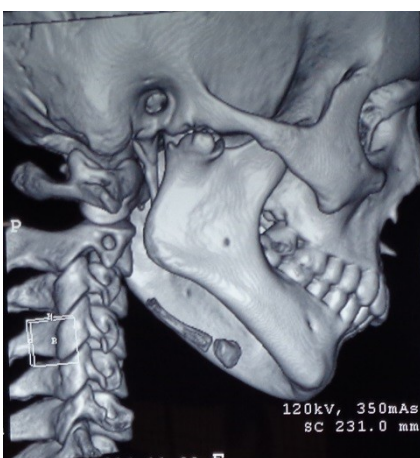


Figure 5.